

The fundamental objectives of early interceptive treatment

Dr. Bradford Edgren discusses normalizing the dentofacial skeleton at an early age

Early interceptive treatment is orthodontic treatment performed at an early age during the early mixed dentition and before the establishment of the permanent dentition. Children as early as 6 years old can exhibit significant crowding, severe dentofacial discrepancies, and facial asymmetries. Patients that present with these problems are good candidates for early orthodontic/dentofacial orthopedic evaluation and treatment.

One of the fundamental objectives of early interceptive treatment is normalizing the dentofacial skeleton. Normalization of the dentofacial components involves creating adequate jaw size to accommodate the eruption of the permanent teeth, correction of facial asymmetries, and improvement in occlusal function. Leaving a patient untreated with a significant orthodontic disparity until after the eruption of the permanent teeth can result in a dental and/or skeletal discrepancy that is too severe to achieve an ideal or even an acceptable orthodontic result.

Consequently, an additional fundamental objective of early orthodontic intervention is the identification of abnormal jaw growth, specifically the excessive growth of the mandible. Recognition of such discrepancies and future growth prior to treatment can forewarn the orthodontist of specific problems to expect during treatment.¹ Patients who exhibit signs of excessive mandibular growth require extended treatment, including early interceptive treatment, to reduce the effects of excessive growth and to harmonize future growth of both jaws.



Bradford Edgren, DDS, MS, earned both his Doctorate of Dental Surgery, as Valedictorian, and his Master of Science in Orthodontics from the University of Iowa, College of Dentistry. He is a Diplomate, American Board of Orthodontics, and a member of the Southwest Component of the Edward H. Angle Society. Dr. Edgren has presented nationally and internationally to numerous orthodontic groups on the importance of orthodontic diagnosis, early interceptive orthodontic treatment, CBCT, and upper airway obstruction. He has been published in *AJO-DO*, the *American Journal of Dentistry*, as well as other orthodontic publications. Dr. Edgren currently has a private practice in Greeley, Colorado.

Educational aims and objectives

This article aims to discuss the fundamental objectives of early interceptive orthodontic treatment.

Expected outcomes

Orthodontic Practice US subscribers can answer the CE questions on page XX to earn 2 hours of CE from reading this article. Correctly answering the questions will demonstrate the reader can:

- Recognize some fundamental objectives of early interceptive treatment.
- Identify early interceptive orthodontic treatment plans.
- Realize some consequences of delaying interceptive treatment.
- Recognize some specific elements for normalization of the dentofacial components.

CE

Another objective is utilization of remaining future growth. By 7 years old, a child's craniofacial skeleton has already achieved 75% of its total adult size. Ninety percent of the average child's craniofacial development has been realized by age 12.² Waiting until all the permanent teeth have erupted may significantly limit the utilization of future growth and dentofacial orthopedics due to the fact that the majority of dentofacial growth has already occurred.

Case report 1

This 7-year 5-month-old female presented with an anterior crossbite, deep overbite, a potential skeletal Class III due to the mandible and a right lingual crossbite (Figure 1). Her CBCT scan, taken on an i-CAT™ Next Generation scanner (Imaging Sciences International), and Ricketts' cephalometric analysis, performed by Rocky Mountain Orthodontics® Data Services® (RMODS®), indicated a severe upper airway obstruction due to an enlarged

Table 1: Fundamental objectives of early intervention
Normalization of skeletal dysplasias and asymmetries
Promote appropriate jaw size to encourage the proper eruption of the permanent teeth
Develop optimum alveolar bone support and appropriate buccal root torque/angulation for permanent teeth
Recognition of upper airway obstruction and establishment of upper airway patency
Improvement of occlusal function
Intervention and termination of recalcitrant habits (i.e., thumb and finger sucking)
Utilization of future growth
Recognition of excessive growth, i.e. the mandible

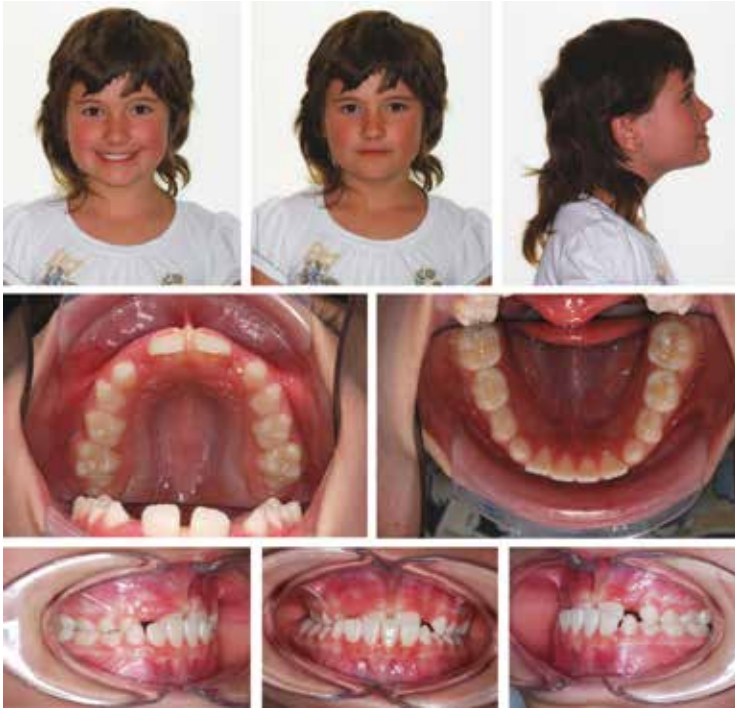

Figure 1: 7-year 5-month-old female presenting with severe deep bite, anterior and right posterior crossbites

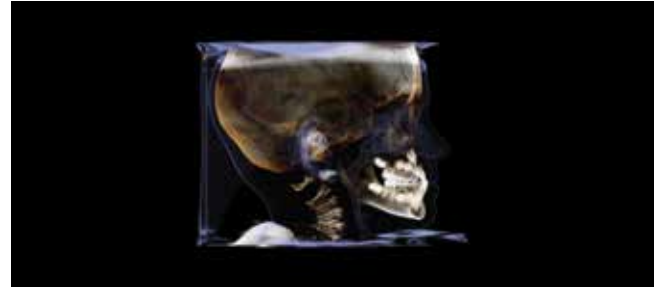


Figure 2: Lateral 3D cephalometric image

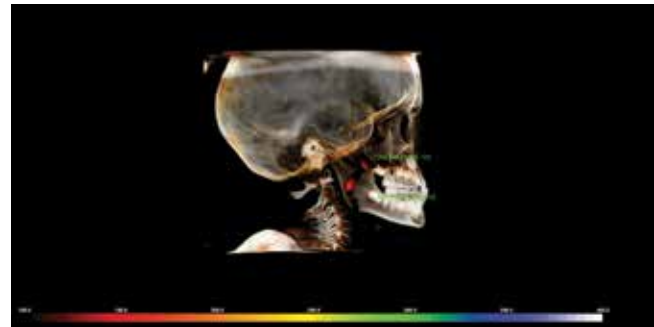


Figure 3: Lateral 3D cephalometric image with 3D airway analysis. Note the severe upper obstruction




Figure 4: Diagnostic lateral cephalometric tracing




Figure 5: Diagnostic frontal cephalometric tracing



Figure 6: Initial growth forecast to maturity without orthodontic treatment

adenoid pad and a skeletal lingual cross-bite pattern due to the maxilla and mandible (Figures 2-5). Her growth forecast to maturity without treatment showed a significant amount of additional mandibular growth and counterclockwise rotation of the occlusal plane, deepening her already deep overbite (Figure 6). The panoramic image revealed an ectopic right maxillary canine with the potential for impaction with the canine overlapping the majority of the lateral incisor root (Figure 7).

Her early interceptive orthodontic treatment plan included rapid maxillary expansion, otolaryngologist referral for tonsillectomy and adenoidectomy, and fixed appliances. Without early interceptive treatment, this patient would require orthognathic surgery to correct her severe skeletal Class III.

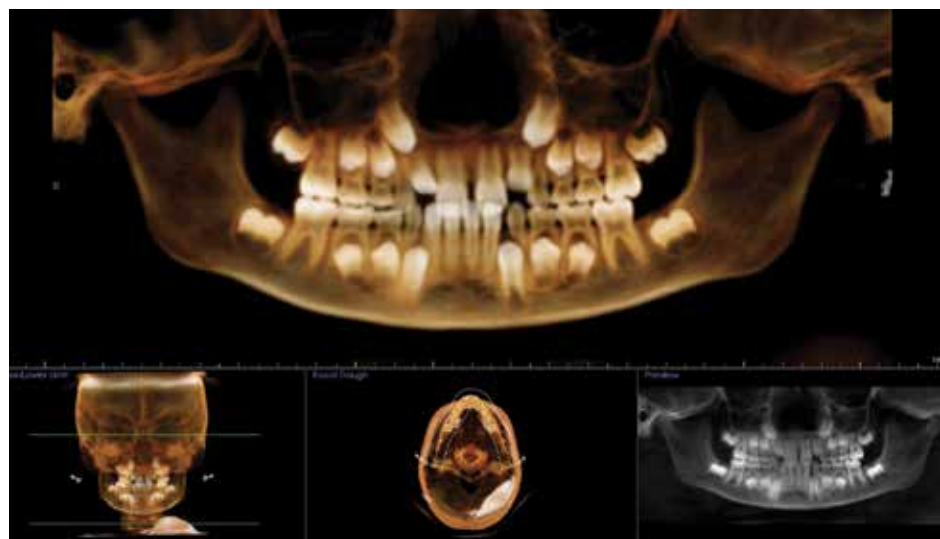

Figure 7: Diagnostic panoramic image demonstrating potentially impacting right maxillary canine

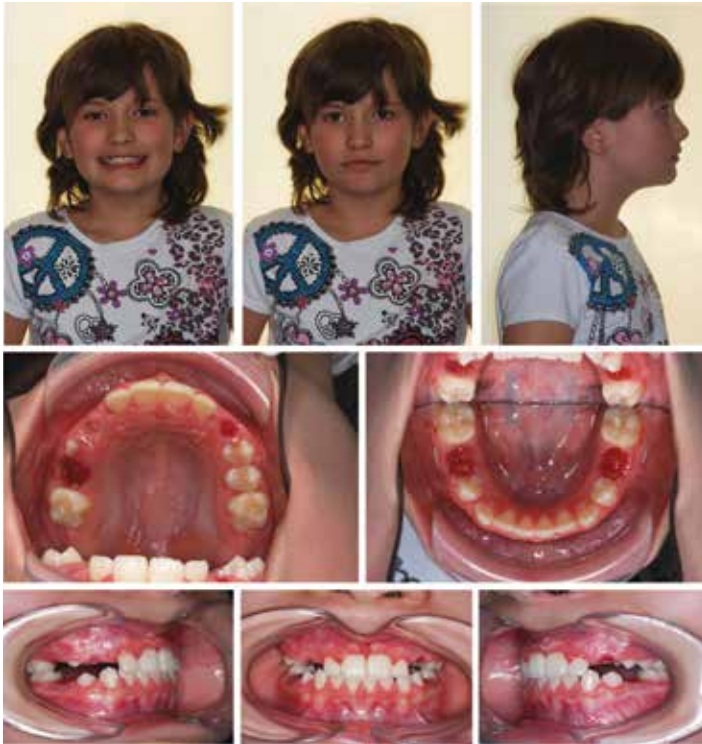

Figure 8: Interim deband photos

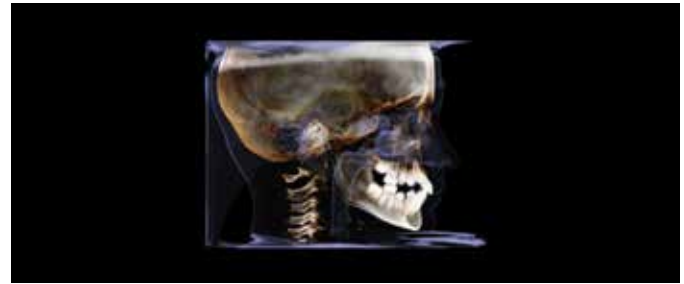

Figure 9: Interim deband 3D lateral cephalometric image

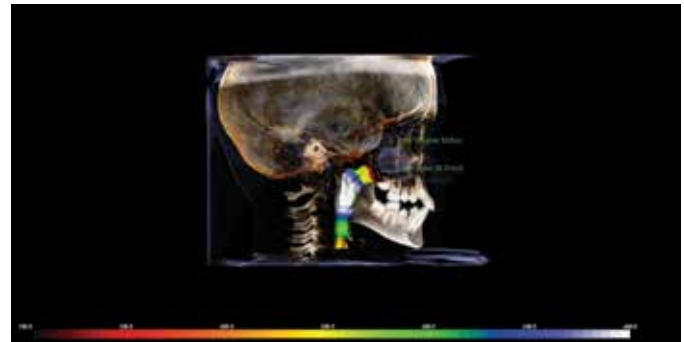


Figure 10: Interim deband 3D lateral cephalometric image with 3D airway analysis. Note the significant improvement in the airway volume with the concomitant straightening of the cervical spine




Figure 11: Interim deband lateral cephalometric tracing




Figure 12: Interim deband frontal cephalometric tracing




Figure 13: Interim deband revised growth forecast to maturity. Note the more harmonious growth of both jaws because of early interceptive treatment

After 20 months of early interceptive treatment, her anterior and right posterior crossbites were corrected (Figure 8). Her skeletal Class III due to the mandible was eliminated, and her upper airway obstruction was removed (Figures 9-11). The skeletal lingual crossbite pattern that was present before treatment has been eliminated (Figure 12). Improvement in the volume of the upper airway following orthodontic expansion, tonsillectomy, and adenoidectomy resulted in significant straightening of the cervical spine. After early interceptive orthodontic treatment, the revised future growth forecast to maturity no longer results in the severe skeletal Class III malocclusion (Figure 13). The interim deband panoramic image shows

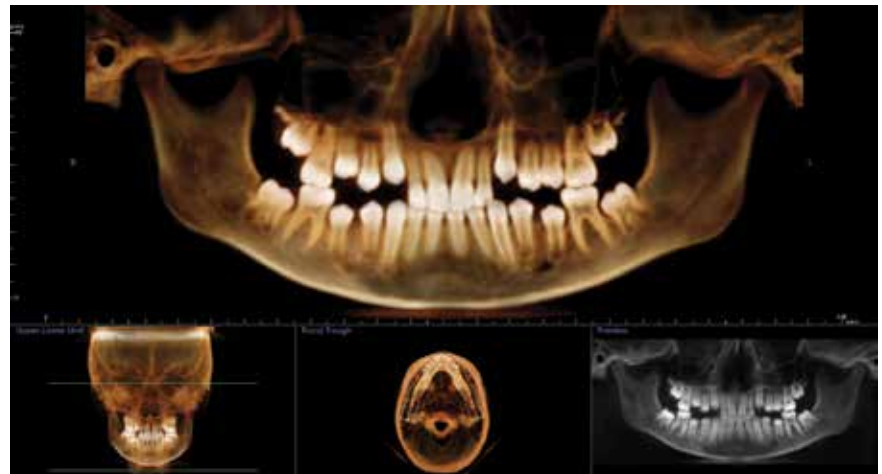


Figure 14: Interim deband panoramic image demonstrating the improved eruption path of the maxillary canines

a significant improvement in the eruption of the remaining teeth, especially the maxillary canines (Figure 14). Follow-up on this patient will require only comprehensive orthodontics, including maxillary and mandibular appliances, after the eruption of the remaining permanent teeth. Seven out of the eight fundamental objectives of early interceptive treatment were met with this patient, resulting in a very favorable outcome. Orthognathic surgery has been avoided, and the remaining treatment entails fixed orthodontic appliances to detail the occlusion and correct the midline discrepancy after the eruption of the remaining permanent teeth.

Permanent teeth can become impacted or begin impacting at an early age. Waiting until the remaining permanent teeth erupt can result in the inability to bring the ectopic and potentially impacting tooth/teeth into proper occlusion, ankylosis, and/or root resorption of adjacent teeth. Addressing impacting and ectopically erupting teeth early provides the opportunity to provide optimum alveolar bone support and appropriate buccal root torque/angulation, which leads to improved occlusal function.

Case report 2

Another 7-year 5-month-old female presented with severe crowding, maxillary constriction with a tendency toward left lingual crossbite, ectopic maxillary and mandibular lateral incisors, and an ectopic left maxillary first molar (Figure 15). Review of her CBCT imaging, as well as a lateral and frontal cephalometric analysis with future growth prediction, demonstrated a skeletal

open-bite pattern due to both jaws, adenoid blockage, a skeletal lingual crossbite pattern due to both jaws, and potentially impacting canines (Figures 16-21).

Several studies have shown that canines will palatally impact with adequate

arch length.³⁻⁵ A study by Al-Nimri, et al., suggested that excessive palatal width may contribute to the frequency of palatal canine impaction.⁶ In contrast, a study by Schindel and Duffy found that patients possessing a transverse discrepancy are more likely

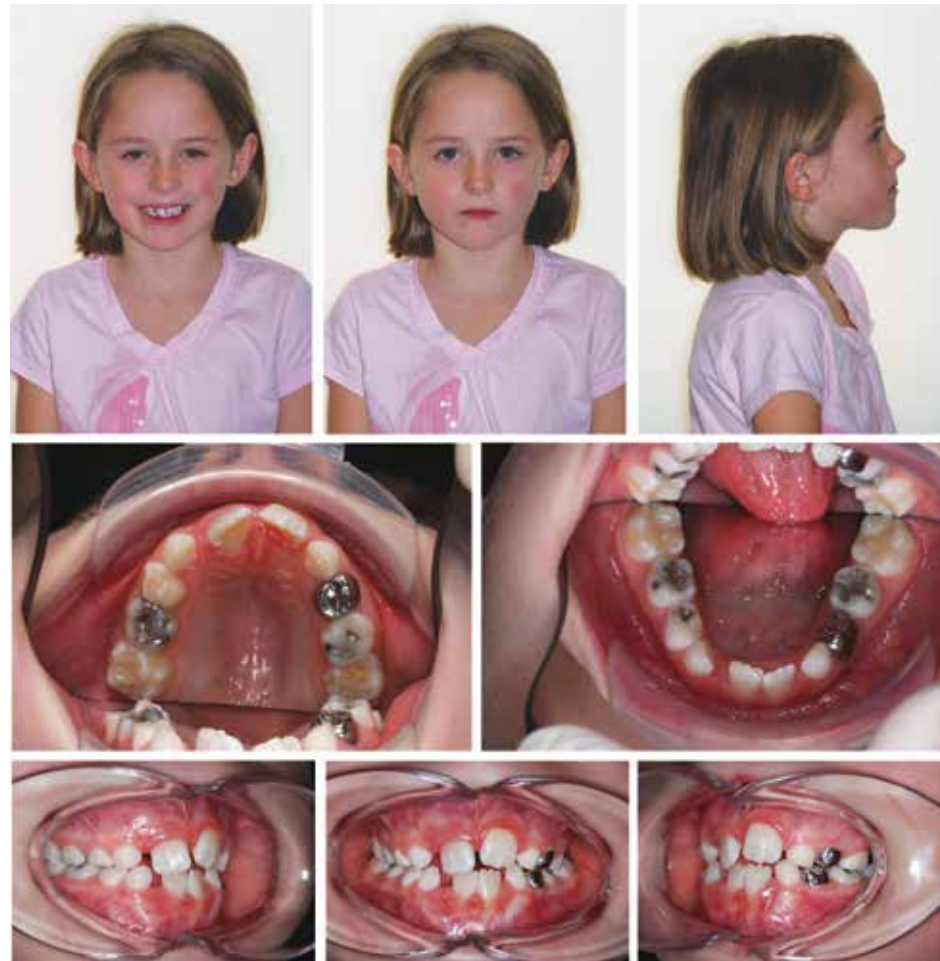


Figure 15: Diagnostic photos of a 7-year 5-month-old female with severe crowding

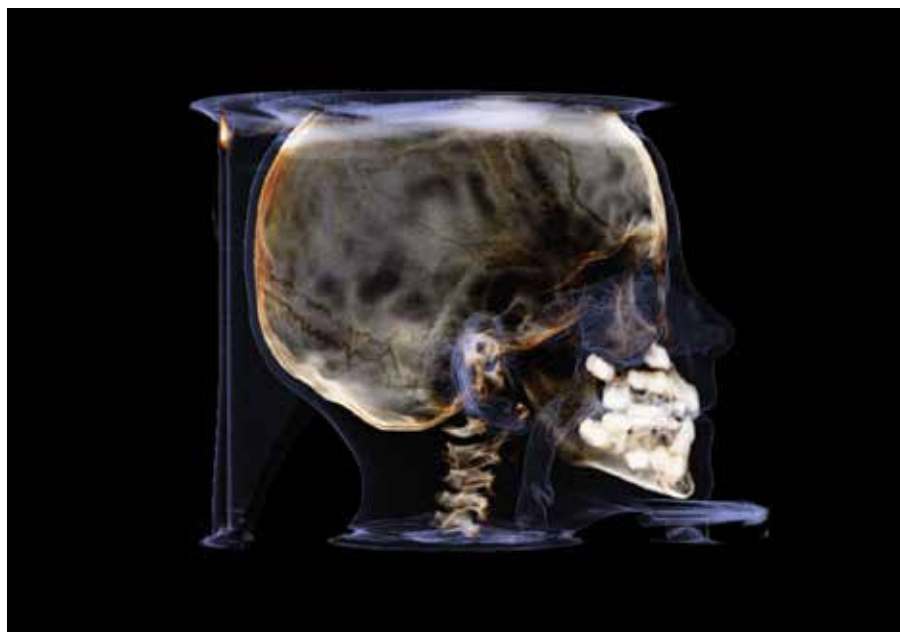

Figure 16: Diagnostic lateral 3D cephalometric image




Figure 17: Diagnostic lateral cephalometric tracing

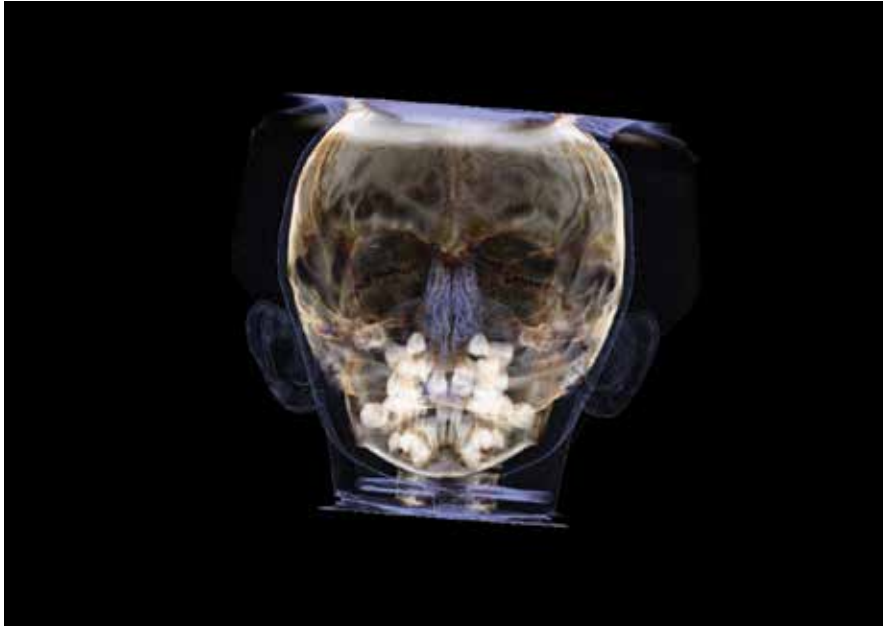

Figure 18: Diagnostic frontal 3D cephalometric image. Note the position of the maxillary lateral incisors and canines




Figure 19: Diagnostic frontal cephalometric tracing demonstrating the skeletal lingual crossbite pattern



Figure 20: Diagnostic lateral growth forecast to maturity

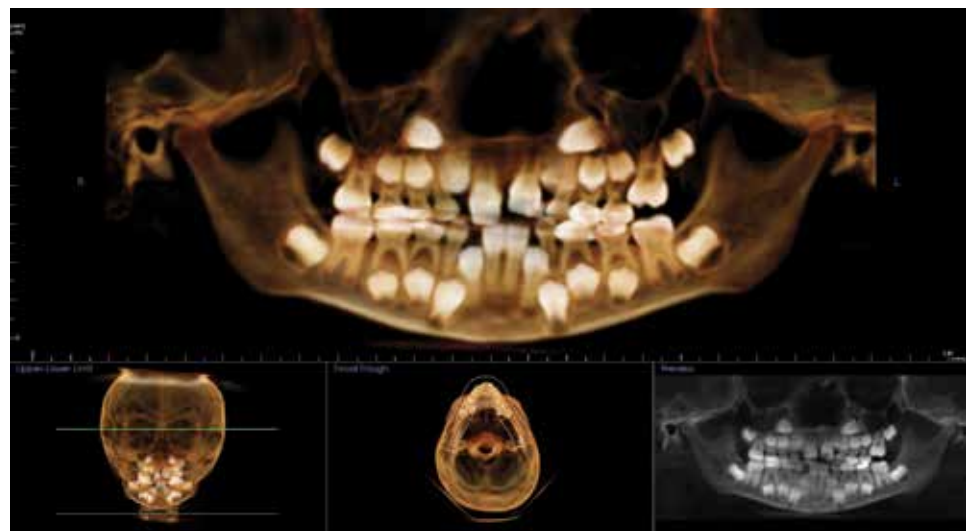


Figure 21: Diagnostic panoramic image illustrating the severe crowding and ectopic maxillary canines

to have an impacted canine than those without.⁷ They also said that the best time to assess a patient for potential maxillary canine impaction is during the early mixed dentition. McConnell, et al., also found that patients with canine impactions demonstrated a profound transverse maxillary anterior arch deficiency.⁸ Miner, et al., stated that many patients may possess skeletal lingual crossbite patterns but dental compensations mask the existing transverse discrepancies.⁹

Many studies have suggested the extraction of the deciduous canine to encourage the favorable eruption of the palatally displaced canine.¹⁰⁻¹⁴ The mean age of the patients in these studies on palatally displaced canines ranged from 11.2 to 13.5 years of age at the period of the late mixed dentition. Bazargani, et al., found that a significant decrease in

arch length occurred in the extraction cases compared to controls. They also stated that maintenance of the maxillary arch length is important during the period of observation.¹⁴ Baccetti, et al., also found that the addition of cervical-pull headgear maintained the space available for maxillary canine eruption and, in fact, improved the rate of eruption of the canine to 87.5% compared to 65.2% in patients with just deciduous canine extraction.¹³ Power and Short and Olive's investigations utilized fixed appliances in combination with deciduous canine extractions to encourage eruption of the permanent canine 62% and 75%, respectively.^{11,12} Furthermore, Power and Short stated that the final result of the deciduous canine removal was conditional upon the initial position of the permanent canine. If horizontal overlap

by the permanent canine of the lateral incisor exceeded half of the width of the incisor root, normal eruption of the permanent canine was unlikely.¹¹

Extraction of the deciduous canines for this patient will not alleviate the severe dental crowding or the impending canine impactions. The previous studies were performed on patients with palatally displaced canines during the late mixed dentition. This patient presented during the early mixed dentition at age 7 years 5 months with midalveolar positioned canines. Extraction of the deciduous canines in this case would have resulted in loss of arch length, hence obstructing the proper eruption of the maxillary canines. Moreover, success of the canine eruption in most of the previously mentioned studies was not based upon just the extraction of

the deciduous canine but also upon the existence of adequate space, or the creation of additional arch length with either fixed appliances or cervical headgear.

Studies by Baccetti, et al., and Schindel and Duffey have reported that rapid maxillary expansion is an effective treatment option for the early interceptive treatment of impacted maxillary canines.^{15, 16} Baccetti, et al., found that patients treated with rapid maxillary expansion had a successful eruption rate of 65.7% of palatally displaced canines, almost 5 times greater than that of the untreated controls (13.6%).¹⁵ Another study by Baccetti, et al., stated that rapid maxillary expansion prior to the peak in skeletal maturation produces more pronounced transverse craniofacial changes at the skeletal level and circummaxillary structures.¹⁷ Rapid maxillary expansion following the pubertal growth spurt results in less skeletal and more dentoalveolar change.

The early interceptive orthodontic treatment plan designed for this patient included the following:

- A referral to an otolaryngologist for tonsillectomy and adenoidectomy
- Bonding of the maxillary arch initially to distalize the ectopic maxillary left first molar into proper position
- Placing a bonded rapid maxillary expander with occlusal coverage after distalization of the maxillary left first molar to create arch length for the ectopic maxillary canines
- Bonding of the mandibular arch with fixed appliances
- A referral to an oral surgeon for canine exposure and guided eruption if the canines appear to be impacting

The panoramic image shown in Figure 22 was made 17 months after the start of treatment on the day of the expander removal. The maxillary dentition was bonded for 9.5 months before placing the rapid maxillary expander. The expander was activated for 2 weeks and then was left in situ for a total of 8 months. Following the removal of the rapid maxillary expander, the posterior segments of the maxillary arch were rebonded. The maxillary laterals and mandibular dentition were bonded 15 months into treatment. Notice that even with maxillary expansion, the canines have both continued to move mesially. Obviously, even with the amount of treatment so far, impaction of the canines is inevitable. Thus, treatment should not be delayed for a patient presenting with these problems. Waiting could result in involvement of both the lateral incisor roots and possibly the left central incisor.

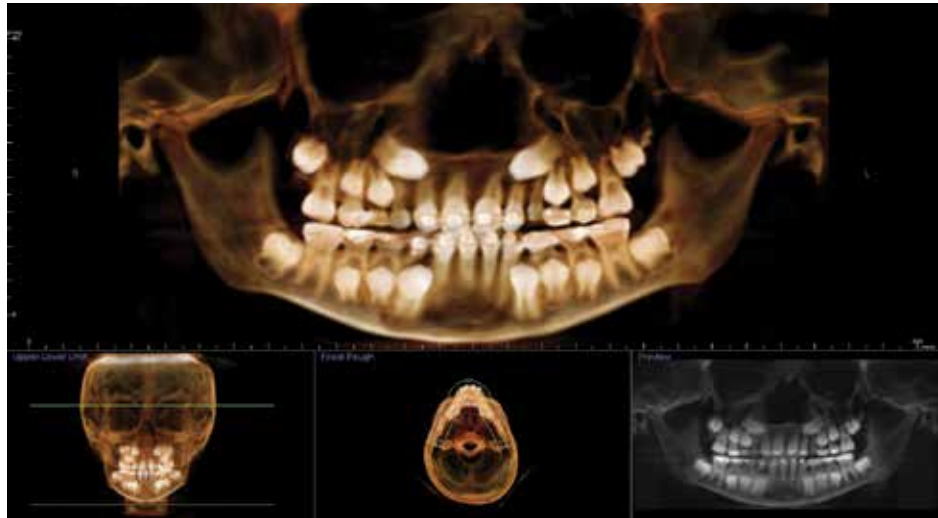


Figure 22: Progress panoramic image. Note the position of the maxillary canines

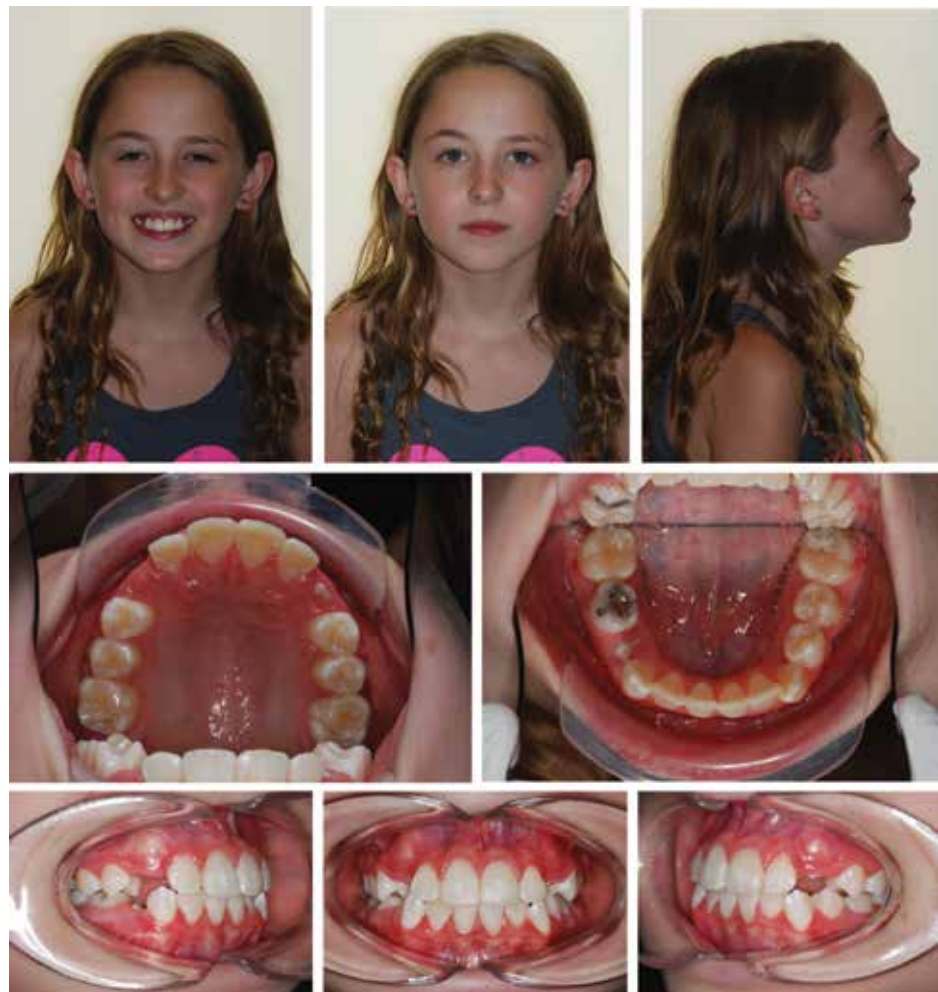

Figure 23: Interim deband photos

Total treatment time for this patient was 42 months to resolve the severe crowding, correct the lingual crossbite, improve the skeletal lingual crossbite pattern, and redirect the ectopically erupting canines; much longer than initially anticipated (Figures 23-28). However, without early intervention, canine exposure and guided eruption techniques

would have been likely required to successfully bring the potentially impacting canines into occlusion. Moreover, the possibility of damage to the adjacent lateral incisor roots would have most likely occurred without early intervention. Seven of the eight fundamental objectives of early interceptive treatment were met in this successful treatment of this

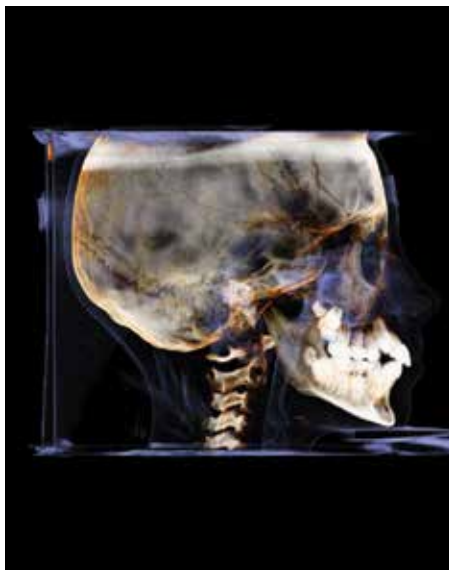

Figure 24: Interim deband 3D lateral cephalometric image




Figure 25: Interim deband lateral cephalometric tracing

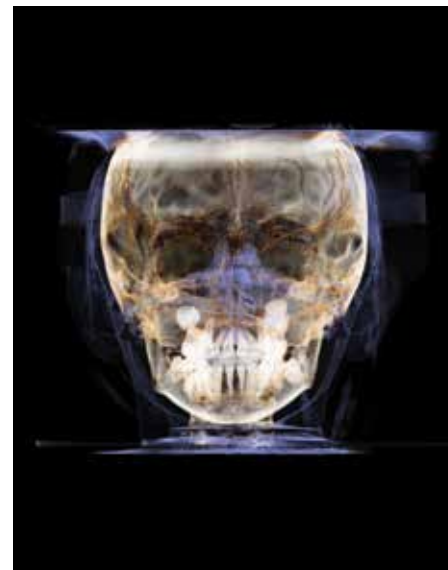

Figure 26: Interim deband 3D frontal cephalometric image




Figure 27: Interim deband frontal cephalometric tracing

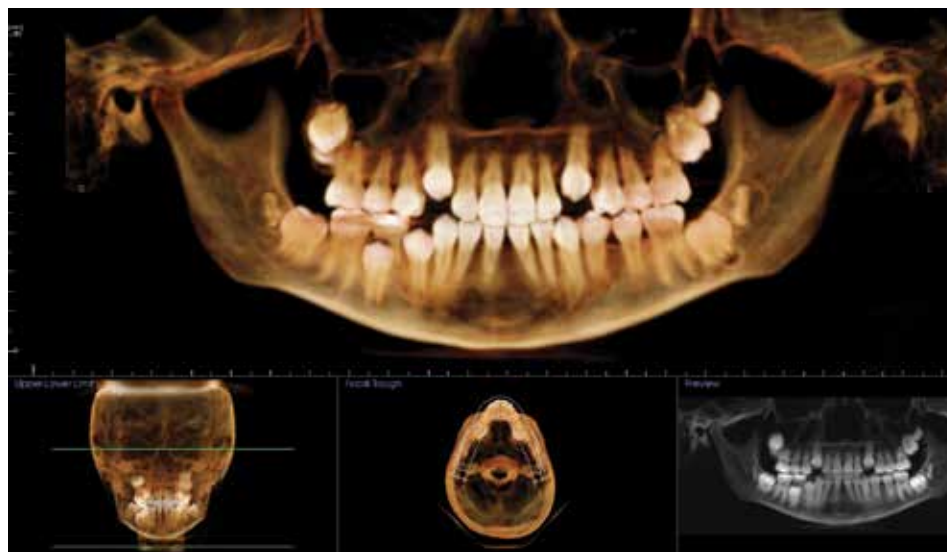

Figure 28: Interim deband panoramic image. Note the improved eruption path of the maxillary canines, the intact lateral incisor roots, and the lack of eruption of the right maxillary second molar due to the impacting third molar

complicated case. To capitalize upon future growth requires time to utilize. Consequently, the length of treatment for this patient is of the least concern when weighed against the success of the final outcome.

As demonstrated in these cases, the benefits of early interceptive treatment were important in the successful outcome in both of these patients. Early recognition of impacting teeth, skeletal dysplasias, upper airway obstructions, transverse discrepancies, and the potential for excessive growth provides for making knowledgeable orthodontic decisions and ultimately successful outcomes. **DP**

REFERENCES

1. Downs WB: Variations in facial relationship. Their significance in treatment and prognosis. *Am J Orthod.* 1948;34(10):812-840.

2. Meredith HV. Growth in head width during the first twelve years of life. *Pediatrics.* 1953;12(4):411-429.

3. Jacoby H. The etiology of maxillary canine impactions. *Am J Orthod.* 1983;84(2):125-132.

4. Peck S, Peck L, Kataja M. The palatally displaced canine as a dental anomaly of genetic origin. *Angle Orthod.* 1994;64(4):249-256.

5. Zilberman Y, Cohen B, Becker A. Familial trends in palatal canines, anomalous lateral incisors, and related phenomena. *Eur J Orthod.* 1990;12(2):135-139.

6. Al-Nimri K, Gharaibeh T. Space conditions and dental and occlusal features in patients with palatally impacted maxillary canines: an aetiological study. *Eur J Orthod.* 2005;27(5):461-5.

7. Schindel RH, Duffy SL. Maxillary transverse discrepancies and potentially impacted maxillary canines in mixed-dentition patients. *Angle Orthod.* 2007;77(3):430-435.

8. McConnell TL, Hoffman DL, Forbes DP, Janzen EK, Weintraub NH. Maxillary canine impaction in patients with transverse maxillary deficiency. *ASDC J Dent Child.* 1996;63(3):190-195.

9. Miner RM, Al Qabandi S, Rigali PH, Will LA. Cone-beam computed tomography transverse analysis. Part 1: Normative data. *Am J Orthod Dentofacial Orthop.* 2012;142(3):300-307.

10. Ericson S, Kuroj J. Early treatment of palatally erupting maxillary canines by extraction of the primary canines. *Eur J Orthod.* 1988;10(4):283-295.

11. Power SM, Short MB. An investigation into the response of palatally displaced canines to the removal of deciduous canines and an assessment of factors contributing to favourable eruption. *Br J Orthod.* 1993;20(3):215-223.

12. Olive RJ. Orthodontic treatment of palatally impacted maxillary canines. *Aust Orthod J.* 2002;18(2):64-70.

13. Baccetti T, Leonardi M, Armi P. A randomized clinical study of two interceptive approaches to palatally displaced canines. *Eur J Orthod.* 2008;30(4):381-385.

14. Bazargani F, Magnuson A, Lennartsson B. Effect of interceptive extraction of deciduous canine on palatally displaced maxillary canine: a prospective randomized controlled study. *Angle Orthod.* 2014;84(1):3-10.

15. Baccetti T, Mucedero M, Leonardi M, Cozza P. Interceptive treatment of palatal impaction of maxillary canines with rapid maxillary expansion: a randomized clinical trial. *Am J Orthod Dentofacial Orthop.* 2009;136(5):657-661.

16. Schindel RH, Duffy SL. Maxillary transverse discrepancies and potentially impacted maxillary canines in mixed-dentition patients. *Angle Orthod.* 2007;77(3):430-435.

17. Baccetti T, Franchi L, Cameron CG, McNamara JA Jr. Treatment timing for rapid maxillary expansion. *Angle Orthod.* 2001;71(6):343-350.