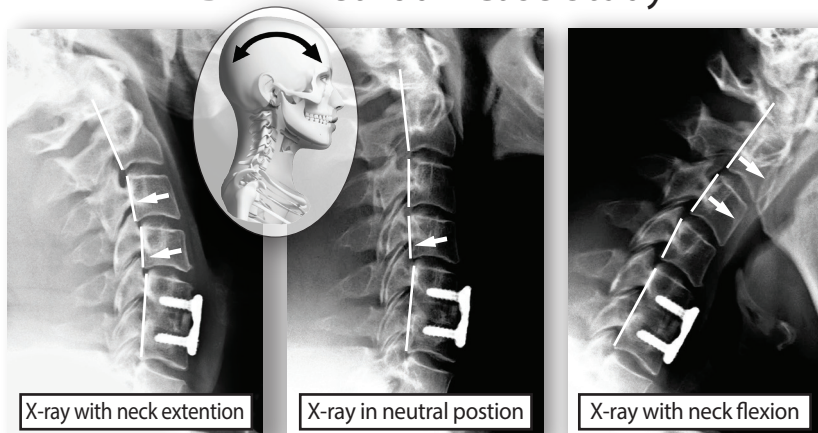


## DMR Method™ Case Study



### Neck and arm pain BEFORE and AFTER neck fusion surgery

Kevin had neck fusion surgery in November 2012. Following the surgery, he continued to have severe neck pain and stiffness. He also developed severe headaches and experienced pain in his arms that steadily escalated. After eight months with no improvement he was told he needed another surgery to fuse more of his neck. He opted to try the DMR Method™ instead.

#### DIAGNOSIS

X-ray evaluation revealed stable appliance fusion of C5-C6, but unstable motion of the vertebrae above the fusion (see x-rays above). DMR Method Evaluation revealed severe fixation/subluxation of the upper neck and upper thoracic spine with reactive muscle spasm and greater occipital nerve irritation (causing headaches), and brachial plexus nerve irritation (causing arm symptoms).

#### TREATMENT

Post-operative Cervical DMR Protocol with a contraindication to any mobilization of the surgically fused C5-C6 segment.

#### OUTCOME

Kevin avoided a second neck surgery. All of his symptoms—neck pain and stiffness, headaches and arm symptoms—were resolved. Due to the surgical fusion in his neck, he was educated about and advised to consistently follow home care and proactive DMR maintenance care.